

Original Contribution

Jumping Into the Future Using Teledermoscopy

Domenico Piccolo, MD;¹ Ketty Peris, MD;¹ Sergio Chimenti, MD;² Giuseppe Argenziano, MD;³ H. Peter Soyer, MD⁴

From the Departments of Dermatology, University of L'Aquila, L'Aquila, Italy;¹ University of Tor Vergata, Rome, Italy;² 2nd University of Naples, Naples, Italy;³ and the University of Graz, Graz, Austria⁴

Address for correspondence:
H. Peter Soyer, MD,
Department of Dermatology,
University of Graz,
Auenbruggerplatz 8, A-8036
Graz, Austria
E-mail:
peter.soyer@kfunigraz.ac.at.

Background. Teledermoscopy uses telecommunication technologies to transfer images of pigmented skin lesions via the Internet for teleconsultation.

Design. Clinical and dermoscopic images of 66 and 43 pigmented skin lesions achieved in two consecutive studies were sent by e-mail to dermatologists with different degrees of experience in dermoscopy for a telediagnosis. All lesions included in these studies were surgically excised and diagnosed histopathologically.

Results. The diagnostic concordance between the face-to-face diagnosis and the telediagnosis was 91% in the first study, whereas, in the second study, it varied from 76.7%–95.3%. The accuracy of the diagnoses in both studies was not related to the quality of the images, but did highly depend on the level of diagnostic difficulty of a given pigmented skin tumor and on the level of experience of each observer.

Conclusions. Teleconsultation of dermoscopic images of pigmented skin lesions via e-mail provides a similar degree of diagnostic accuracy as “face-to-face” diagnosis when the diagnosis is made by a dermatologist confident with dermoscopy. (SKINmed. 2002;1:20–24) ©2002 Le Jacq Communications, Inc.

The incidence of cutaneous melanomas has increased significantly in the last few decades. The early diagnosis of this malignant neoplasm represents a continuous challenge for dermatologists. Dermoscopy is a noninvasive technique for the diagnosis of pigmented skin lesions that allows the evaluation of structures that are not visible on clinical examination.^{1–3} Using this technique it is possible to differentiate between melanocytic and nonmelanocytic skin lesions and verify their benign or malignant nature. As already demonstrated by Binder et al.,⁴ when performed by experts, dermoscopy increases the diagnostic accuracy of pigmented skin lesions.

The introduction of “telemedicine” dates from the beginning of 1970. Telemedicine has been employed to increase access to health care for people in places that are not easily accessible, for example, those in remote areas, in urban settings, or prisons—wherever access to specialized centers is limited. As “telehealth” technology becomes more and more prevalent, affordable, and accessible both to patients and clinicians, telehealth practitioners are increasingly participating in telemedicine programs. Telemedicine is already a well-integrated part of medical practice, particularly in fields such as radiology and pathology, where digital images are important diagnostic and therapeutic tools.

Teledermatology has a recent history. The first application in this field is credited to Perednia and Brown⁵ in 1995 who reported their experience in a rural area of Oregon, where there were only two dermatologists for a large population. In this preliminary study, however, no detailed results concerning the diagnostic validity of this method were presented. Later on, in 1997, Zelickson and Homan⁶ emphasized the advantages of teledermatology by using a standard telephone line in a nursing home in Minneapolis, MN. Digital images of cutaneous disorders were sent by a nurse to a number of dermatologists who performed preliminary diagnoses on monitors, availing themselves of the “store-and-forward” method. Such telediagnoses revealed a high diagnostic concordance (88%) compared to those made by the on-site dermatologist.

In the last few years, several studies have shown the validity of teledermatology^{7–12} thus demonstrating the potential of this technique as a unique tool, especially in communities where a dermatologic service is not available.

Teledermoscopy: State of the Art

The introduction of digital dermoscopy has changed the clinical approach and the management of pigmented skin lesions, opening a new morphologic dimension. Often, general practitioners in rural areas have to send their patients to specialized centers for the diagnosis of certain pigmented skin lesions, which means inconvenience for the patient and high costs for the medical care system.

Teledermoscopy represents the latest development of teledermatology. Dermoscopic images of pigmented skin lesions can be transmitted through tele-communication networks, in “real time” or using the “store-and-forward” system. In 1998, Provost et al.¹³ reported a teledermoscopic study showing a high concordance in the diagnosis of atypical (dysplastic) melanocytic nevi and early melanoma between four different clinicians when comparing conventional slides to transmitted, compressed, digitized images. In 1999, we reported a teledermoscopic study on 66 pigmented skin lesions¹⁴ that were diagnosed on a “face-to-face” basis at the Department of Dermatology, University of L’Aquila, Italy, by a dermatologist expert on pigmented skin tumors. For each lesion, clinical and dermoscopic digital images were stored in a Targa format file (870 kilobyte) compressed into a JPEG (40–80 kilobyte) and sent by e-mail on the basis of the “store-and-forward” method, to a dermoscopy expert in the Department of Dermatology, University of Graz, Austria, for telediagnosis to be performed on a standard resolution color monitor. The compression of the images was necessary to make the transmission faster.

For each lesion a dermatologist expert on pigmented skin lesions established the level of diagnostic difficulty (i.e., high, medium, or low), on the basis of the knowledge of both dermoscopic and histopathologic data. Furthermore, a professional photographer assessed the image quality on the monitor (i.e., excellent, good, or sufficient). All lesions were surgically excised at the Department of Dermatology, University of L’Aquila, Italy (after informed consents were signed by the patients) and diagnosed histopathologically by a dermatopathologist (H.K.) at the Department of Dermatology, University of Graz, Austria. Our results showed high values of diagnostic concordance between “face-to-face” diagnosis and the telediagnosis (90.9%) and between “face-to-face” diagnosis and histopathology (92.4%).

The diagnostic concordance between telediagnosis and histopathology was less accurate (86.4%) but this difference was not statistically significant (Wilcoxon test, $p=0.10$). The diagnostic accuracy was influenced by the level of diagnostic difficulty of a given pigmented skin lesion (Spearman correlation, $p=0.014$) but, interestingly, it did not depend on the quality of the image (Spearman correlation, $p=0.833$). The high diagnostic concordance achieved in this study was probably due to the very similar level of competence in dermoscopy between the two groups of investigators. In order to verify this assumption we performed a multicenter study on teledermoscopy of pigmented skin lesions, comparing “face-to-face” diagnosis with telediagnosis made by clinicians with different degrees of experience in dermoscopy.¹⁵ Digital clinical and dermoscopic images from 43 pigmented skin tumors (11 melanomas, 23 melanocytic nevi, three basal-cell carcinomas, three lentiginos, two seborrheic keratoses and one angiokeratoma) were sent by e-mail, using the “store-and-forward” method to eleven colleagues (six dermatologists, three residents in dermatology, one

oncologist, and one internist). In this study all images were stored at the Department of Dermatology, University of Graz, Austria, and then sent to 10 different centers for telediagnosis. All lesions were surgically excised and histopathologically examined at the Department of Dermatology, University of Graz, Austria. The final clinical diagnosis was made by a dermatologist, expert in pigmented skin lesions, on the basis of clinical features and dermoscopic findings. All patients gave their informed consent for surgical excision of the lesions. Eleven colleagues performed their telediagnoses on a standard resolution color monitor from centers located in Italy (three different centers), Austria (two), Switzerland (one), USA (one), England (one), Germany (one), and Japan (one). For each case they received, via e-mail, two images (one clinical and one dermoscopic) (Figure 1) and were provided with essential clinical data, such as age and sex of the patient and location of the lesion. All images included in this study were compressed in JPEG format file to reduce the

Dermoscopic images of pigmented skin lesions can be transmitted through a telecommunications network.

Jumping Into the Future Using Teledermoscopy

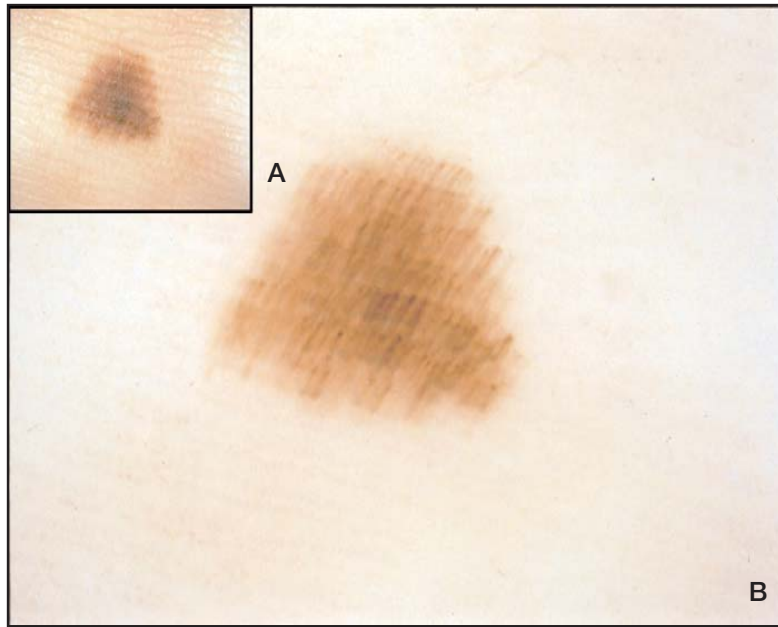


Figure 1. Clinical (A) and dermoscopic (B) images of an acral nevus

size from 17 megabytes (PICT format file) in the original image to 53 kilobytes in the final image. Nevertheless, the compressed image was virtually identical to the noncompressed one, as already demonstrated by Kittler et al.¹⁶ in 1998. The level of experience on dermoscopy was assessed for each investigator on the basis of the number of years of specialization on pigmented skin tumors, number of years of work on dermoscopy, the number of seminars and/or workshops on dermoscopy attended and, finally, the number of publications on this topic. The diagnostic concordance between face-to-face diagnosis and telediagnosis as well as histopathologic diagnosis was calculated by κ statistics. Our results showed that the colleagues who made the face-to-face diagnosis obtained a κ value of 0.740, recognizing correctly 39 out of 43 pigmented skin lesions. The best telediagnoses were performed by three participants with a high degree of experience on dermoscopy. In such cases, the κ value was 0.870 (41/43), 0.822 (40/43), and 0.756 (39/43), respectively. Interestingly, these results were higher than those obtained on a face-to-face basis. The worst results were achieved by two colleagues with a low level of experience in this field: they made the correct telediagnosis in 33 out of 43 cases ($\kappa=0.350$) and in 34 out of 43 cases ($\kappa=0.396$), respectively. Notably, also in this study, the diagnostic concordance was highly influenced by the level of diagnostic difficulty, as established by an expert dermoscopist but not by the quality of the images evaluated by a professional photographer.

On the basis of these studies on teledermoscopy, we showed that accurate diagnoses can be made on a “face-to-face” basis as well as using a standard resolution color monitor, provided that the dermatologist is experienced in dermoscopy.

The equipment used in our studies is commercially available and not very expensive. No specialized technical training is necessary for telematic technologies. The choice of the e-mail (Internet) as the telematic network is possible when using compressed JPEG images (at a small size); for a “real time” consultation or noncompressed images, integrated services digital network (ISDN) lines, optical fibers, or satellites are required, but their cost, at the moment, is high.

Braun et al.¹⁷ have recently reported a study of teledermoscopy in Switzerland, in which six dermatologists in private practice sent clinical and dermoscopic images of 55 pigmented skin lesions to the Department of Dermatology of the University of Geneva for teleconsultation, over a period of 6 months. Their results showed that the diagnostic accuracy of teledermoscopy was superior to the one obtained on a face-to-face basis, suggesting that patients benefit from teleconsultation.

In conclusion, the use of teledermoscopy for the diagnosis of pigmented skin lesions could contribute significantly to reduce the waiting time and work load in a dermatologic routine, to spare the patient unnecessary distress, and ultimately save public money while providing a faster, reliable, and more efficient service.

Future Considerations

Telemedicine applied to the field of pigmented skin lesions could be further expanded in the next few years. One possibility could be teledermatopathology. In some difficult cases, the combination of clinical and dermoscopic images together with the histopathologic slide can be crucial to obtaining the best diagnosis. Recently, we performed a teledermatopathology study using telematic technologies to transfer images of cutaneous biopsies via e-mail to remote dermatopathologists for teleconsultation.¹⁸ Twenty specimens of cutaneous disease were selected from the archive of the Department of Dermatology, University of Graz, Austria. For each case, three or four images were stored at different magnifications

Jumping Into the Future Using Teledermoscopy

using a digital camera (Kodak DCS 460, Rochester, NY) connected to a conventional microscope (Olympus BX 50, Tokyo, Japan). All images were compressed into JPEG format files and sent via e-mail to 16 colleagues (11 dermatopathologists and five pathologists) in 15 centers in six different countries. Six weeks later the participants received the hematoxylin and eosin specimens for a conventional diagnosis. The aim of this study was to verify the validity and feasibility of teledermatopathology and to compare the inter- and intraobserver agreement between the telediagnoses and the conventional histopathologic diagnoses. The diagnosis obtained by assessing clinical features and histopathological findings was assumed as the gold standard.

Our results showed that, on average, 78% of the telediagnoses were correct, whereas conventional diagnoses were correct in 80% of cases. Two out of 16 observers (12.5%) obtained an excellent interobserver agreement ($\kappa > 0.75$), 10 out of 16 participants (62.5%) a fair to good agreement ($0.40 < \kappa < 0.75$), and four out of 16 observers (25%) a poor agreement ($\kappa < 0.40$). This study confirms that teledermatopathology may be a reliable technique for the diagnosis of cutaneous diseases in general, and of pigmented skin tumors specifically, especially when there are no experts available.

Further development could include the teleautomated diagnosis of cutaneous melanoma. In the last few years, some studies about computer-aided diagnosis of pigmented skin lesions have been published.¹⁹⁻²⁴ The main research objective is the development of an automatic diagnostic system that can be used in daily clinical practice of both melanocytic and non-melanocytic pigmented skin tumors. Obviously, these systems need to be tested on a large number of lesions before they can be used in the dermoscopic routine.

We have been working with an independent group of engineers for two years on a computer-aided diagnosis software, named Nevuscreen, that is based on an automatic "ABCD" rule of dermoscopy, as described by Nachbar et al.²⁵ in 1994 (Figure 2). We could imagine a server on the Internet where dermatologists, using standardized equipment, could send their cases to receive an automatic ABCD index and a proposal for the management of a specific lesion. At




Figure 2. Computer aided diagnosis using the Nevuscreen software

present, this is only a hypothetical possibility for the future, although we think it will become a reality in a short time.

REFERENCES

- 1 Pehamberger H, Binder M, Steiner A, et al. In vivo epiluminescence microscopy: improvement of early diagnosis of melanoma. *J Invest Dermatol.* 1993;100:356-362.
- 2 Soyer HP, Smolle J, Leitinger G, et al. Diagnostic reliability of dermoscopic criteria for detecting malignant melanoma. *Dermatology.* 1994;190:25-30.
- 3 Argenziano G, Soyer HP. Dermoscopy of pigmented skin lesions—a valuable tool for early diagnosis of melanoma. *Lancet Oncol.* 2001;2:443-449.
- 4 Binder M, Schwarz M, Winkler A, et al. Epiluminescence microscopy. A useful tool for the diagnosis of pigmented skin lesions for formally trained dermatologists. *Arch Dermatol.* 1995;131:286-291.
- 5 Perednia DA, Brown NA. Teledermatology: one application of telemedicine. *Bull Med Libr Assoc.* 1995;83:42-47.
- 6 Zelickson BD, Homan L. Teledermatology in the nursing home. *Arch Dermatol.* 1997;133:171-174.
- 7 Kvedar JC, Edwards RA, Menn ER, et al. The substitution of digital images for dermatologic physical examination. *Arch Dermatol.* 1997;133:161-167.
- 8 Norton SA, Burdick AE, Phillips CM, et al. Teledermatology and underserved populations. *Arch Dermatol.* 1997;133:197-200.
- 9 Phillips CM, Burke WA, Shechter A, et al. Reliability of dermatology teleconsultations with the use of teleconferencing technology. *J Am Acad Dermatol.* 1997;37:398-402.
- 10 Leshner JL, Davis L, Gourdin FW, et al. Telemedicine evaluation of cutaneous diseases: a blinded comparative study. *J Am Acad Dermatol.* 1998;38:27-31.
- 11 Lowitt MH, Kessler II, Kauffman CL, et al. Teledermatology and in-person examinations. A comparison of patients and physician perceptions and diagnostic agreement. *Arch Dermatol.* 1998;134:471-476.
- 12 Loane MA, Corbett R, Bloomer SE, et al. Diagnostic accuracy and clinical management by realtime teledermatology. Results from the Northern Ireland arms of the UK Multicentre Teledermatology Trial. *J Telemed Telecare.* 1998;4:95-100.
- 13 Provost N, Kopf AW, Rabinovitz HS, et al. Comparison of conventional photographs and telephonically transmitted compressed digitized images of melanomas and dysplastic nevi. *Dermatology.* 1998;196:299-304.
- 14 Piccolo D, Smolle J, Wolf IH, et al. "Face-to-face" versus telediagnosis of pigmented skin tumors: a teledermoscopic study. *Arch Dermatol.* 1999;135:1467-1471.

Jumping Into the Future Using Teledermoscopy

- 15 Piccolo D, Smolle J, Argenziano G, et al. Tele-dermoscopy—results of a multicentric study on 43 pigmented skin lesions. *J Telemed Telecare*. 2000;6:132–137.
- 16 Kittler H, Seltenheim M, Pehamberger H, et al. Diagnostic informativeness of compressed digital epiluminescence microscopy images of pigmented skin lesions compared with photographs. *Melanoma Res*. 1998;8:255–260.
- 17 Braun RP, Meier ML, Pelloni F, et al. Teledermoscopy in Switzerland: a preliminary evaluation. *J Am Acad Dermatol*. 2000;5:770–775.
- 18 Piccolo D, Soyer HP, Burgdorf W, et al. Concordance between telepathologic diagnosis and conventional histopathologic diagnosis: a multi-observer store-and-forward study on 20 skin specimens. *Arch Dermatol*. In press.
- 19 Binder M, Steiner A, Schwarz M, et al. Application of an artificial neural network in epiluminescence microscopy pattern analysis of pigmented skin lesions: a pilot study. *Br J Dermatol*. 1994;130:460–465.
- 20 Binder M, Kittler H, Seeber A, et al. Epiluminescence microscopy-based classification of pigmented skin lesions using computerized image analysis and an artificial neural network. *Melanoma Res*. 1998;8:261–266.
- 21 Seidenari S, Pellacani G, Pepe P. Digital videomicroscopy improves diagnostic accuracy for melanoma. *J Am Acad Dermatol*. 1998;39:175–181.
- 22 Seidenari S, Pellacani G, Giannetti A. Digital videomicroscopy and image analysis with automatic classification for detection of thin melanoma. *Melanoma Res*. 1999;9:163–171.
- 23 Andreassi L, Perotti R, Rubegni P, et al. Digital dermoscopy analysis for the differentiation of atypical nevi and early melanoma: a new quantitative semiology. *Arch Dermatol*. 1999;135:1459–1465.
- 24 Rubegni P, Ferrari A, Cevenini G, et al. Differentiation between pigmented Spitz nevus and melanoma by digital dermoscopy and stepwise logistic discriminant analysis. *Melanoma Res*. 2001;11:37–44.
- 25 Nachbar F, Stolz W, Merkle T, et al. The ABCD rule of dermoscopy: high prospective value in the diagnosis of doubtful melanocytic skin lesions. *J Am Acad Dermatol*. 1994;30:551–559.