

Dermoscopic Classification of Atypical Melanocytic Nevi (Clark Nevi)

Rainer Hofmann-Wellenhof, MD; Andreas Blum, MD; Ingrid H. Wolf, MD; Domenico Piccolo, MD; Helmut Kerl, MD; Claus Garbe, MD; H. Peter Soyer, MD

Objectives: To create a dermoscopic classification of atypical melanocytic nevi (Clark nevi) and to investigate whether individuals bear a predominant type.

Design: Digital dermoscopic images of Clark nevi were classified according to structural features, ie, reticular, globular, or homogeneous patterns or combinations of these types. The nevi were also characterized as central hypopigmented or hyperpigmented, eccentric peripheral hypopigmented or hyperpigmented, or multifocal hypopigmented or hyperpigmented.

Setting: Two pigmented skin lesion clinics.

Patients: We examined 829 Clark nevi on 23 individuals.

Main Outcome Measure: A reliable dermoscopic classification of Clark nevi and frequency of different dermoscopic types.

Results: Using the dermoscopic classification, the 829

Clark nevi were classified as follows: 221 (26.7%) as reticular, 167 (20.1%) as reticular-homogeneous, 148 (17.9%) as globular-homogeneous, 112 (13.5%) as reticular-globular, 89 (10.7%) as homogeneous, 84 (10.1%) as globular, and 8 (1.0%) as unclassified. Most individuals were prone to a predominant type of Clark nevus. Seven individuals (30%) showed a single type of Clark nevus in more than 50% of their nevi and 5 (22%) in more than 40% of their nevi.

Conclusions: The proposed dermoscopic classification of Clark nevi is easily applicable and allows a detailed characterization of the different dermoscopic types of Clark nevi. Knowledge of these dermoscopic types should reduce unnecessary surgery for benign melanocytic lesions. Exact classification of the different types of Clark nevi is a necessary prerequisite for further clinical, dermoscopic, and histopathologic studies, which will give new insights in the biology of acquired melanocytic nevi.

Arch Dermatol. 2001;137:1575-1580

CLARK NEVI (atypical melanocytic nevi) are acquired melanocytic lesions that are well-known clinically by physicians and especially by dermatologists. Clark nevi are named for Wallace H. Clark, Jr, MD, whose group first drew attention to this particular type of nevus in studies of numerous melanocytic nevi in patients with concomitant melanomas.¹ This melanocytic nevus, originally designated *B-K mole*,¹ has also been called *dysplastic nevus*^{2,3} or *atypical mole*.⁴ We prefer to use the nomenclature set forth by Ackerman and Magana-Garcia⁵ and designate these acquired melanocytic lesions as *Clark nevi*.

In the first published report of this special variant of acquired melanocytic nevi, Clark et al¹ described the enormous clinical variability of these melanocytic lesions,

which ranged from fewer than 10 to more than 100, were prominent on the upper part of the trunk and the extremities, and varied in size (5-15 mm), shape, and color. However, in many subsequent articles about dysplastic nevi, the clinical features were not clarified,⁶⁻⁸ and a detailed description of the many different dermoscopic features has not yet been published.

See also pages 1583, 1590, and 1641

In the present study, we used dermoscopy to classify Clark nevi into different types. The purposes of this classification were (1) to create an easily applicable and reproducible classification of Clark nevi, and (2) to investigate whether individuals bear a predominant type of Clark nevi.

From the Departments of Dermatology, University of Graz, Graz, Austria, (Drs Hofmann-Wellenhof, Wolf, Kerl, and Soyer), University of Tübingen, Tübingen, Germany (Drs Blum and Garbe), and University of L'Aquila, L'Aquila, Italy (Dr Piccolo).

PATIENTS AND METHODS

Patients described herein attended the pigmented skin lesion clinics affiliated with the departments of dermatology at the University of Graz, Graz, Austria, or the University of Tübingen, Tübingen, Germany.

We included in the study only patients with a history of histopathologically proven Clark nevus (n=15) or melanoma (n=8) and more than 10 Clark nevi. Patients received routine clinical care, and no study-specific procedures were performed. The clinical diagnosis of Clark nevi (atypical melanocytic nevi) was established when at least 3 of the following characteristics were present: (1) diameter of greater than 5 mm, (2) ill-defined borders, (3) irregular margin, (4) varying shades in the lesion, and (5) presence of papular and macular components.⁹ All Clark nevi were documented. Images of each nevus were viewed using the screen of a dermoscopic workstation (FotoFinder; TeachScreen, Bad Birnbach, Germany) or color reproductions obtained from a photographic-quality printer (Kodak XLS 8600; Eastman Kodak Co, Rochester, NY) connected to a digital epiluminescence microscopic teledermatology workstation (Vanguard Imaging LTD, Cambridge, Mass). All images were viewed by at least 2 investigators (A.B. and R.H.-W., I.H.W., or H.P.S.).

The nevi were classified according to morphologic criteria (**Table 1**). Within a lesion, we identified the following main structural components: reticular pigment network,¹⁰⁻¹³ pigmented globules,¹⁰⁻¹³ and homogeneous pigmentation.^{13,14} When a clear predominance of one of these structural components was seen, the nevus was classified as reticular, globular, or homogeneous. In the case of the dominant presence of 2 structural components, the nevus was classified as reticular-globular, reticular-homogeneous, or globular-homogeneous (**Figures 1, 2, 3, 4, 5, 6, and 7**). In addition, the distribution of the pigmentation was classified as central hyperpigmented or hypopigmented, eccentric peripheral hyperpigmented or hypopigmented, and multifocal hyperpigmented or hypopigmented (**Figures 8, 9, 10, 11, and 12**). In cases where hyperpigmentation and hypopigmentation were present, classification was based on the predominant distribution of color. **Table 2** presents a detailed description of classification of Clark nevi by pigmentation.

We studied 23 individuals (15 male and 8 female). The median age was 33 years (range, 7-60 years). There were 3 patients with skin type I, 15 with skin type II, and 5 with skin type III.

We examined 829 Clark nevi on all 23 patients. The number of nevi in each individual ranged from 14 to 59. Nevi were classified into the dermoscopic categories specified in **Table 3**. No single Clark nevus in this study showed all 3 structural components. The 8 unclassified nevi were totally hypopigmented; thus, further classification was not feasible.

The distribution of pigmentation in the different dermoscopic types of Clark nevi is given in detail in **Table 3**. Uniform pigmentation was found most frequently in all but 2 of the 6 types; the reticular-globular and the reticular-homogeneous types showed predominantly multifocal hyperpigmentation or hypopigmentation.

In analyzing the Clark nevi of each subject individually, we observed that the reticular pattern was the most common in 10 individuals (43%), followed by the globular-homogeneous (n=4 [17%]), reticular-globular (n=4 [17%]), reticular-homogeneous (n=3 [13%]), and globular (n=2 [9%]) patterns. Thirteen individuals (57%) had at least 1 nevus of each dermoscopic type. Eight individuals (35%) had 5 different dermoscopic types, whereas 2 individuals (9%) had only 4 different types.

Most individuals had 1 predominant type of Clark nevus. Seven individuals (30%) showed 1 type of Clark nevus in more than 50% of their nevi; 5 individuals (22%) showed 1 type in more than 40% of their nevi. In these 12 individuals, the predominant type of Clark nevus was reticular (n=7), reticular-homogeneous (n=2), reticular-globular (n=1), globular (n=1), and globular-homogeneous (n=1). Among the 7 individuals in whom the predominant type of Clark nevus was reticular, 6 had skin type II.

COMMENT

Based on the present morphologic study of 829 Clark nevi (atypical melanocytic nevi) in 23 patients, we classified Clark nevi into the following 6 dermoscopic types: reticular, globular, homogeneous, reticular-globular, reticular-homogeneous, and globular-homogeneous. Using this dermoscopic classification, we were able to classify

Table 1. Definitions of Major Dermoscopic Types of Clark Nevi (Atypical Melanocytic Nevi)

Type	Definition and Predominant Features	Figure*
Reticular	Pigment network	1
Globular	Numerous globules or dots	2
Homogeneous	Homogeneous brown pigmentation	3
Reticular-globular	≥3 Meshes of pigment network with ≥3 globules or dots	4
Reticular-homogeneous	≥3 Meshes of pigment network with homogeneous brown pigmentation in at least one quarter of the lesion	5
Globular-homogeneous	≥3 Globules or dots with homogeneous brown pigmentation in at least one quarter of the lesion	6
Unclassified	No specific pattern	7

*Each type of nevus is depicted in the following figures.

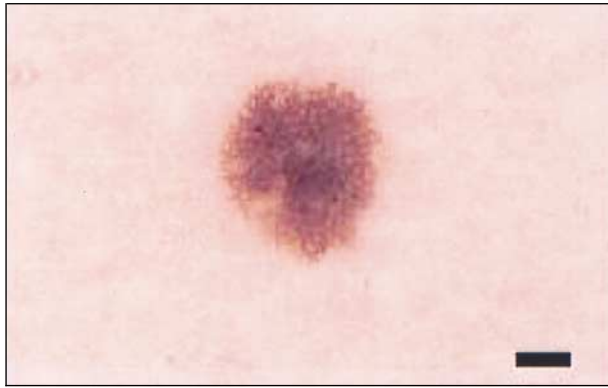

Figure 1. Reticular type of Clark nevus. Scale bar indicates 1 mm.

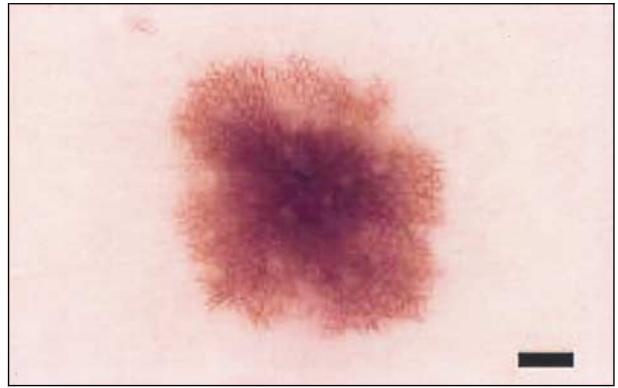

Figure 5. Reticular-homogeneous type of Clark nevus. Scale bar indicates 1 mm.

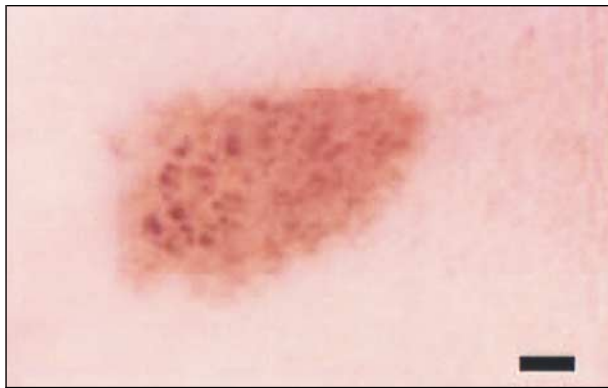

Figure 2. Globular type of Clark nevus. Scale bar indicates 1 mm.

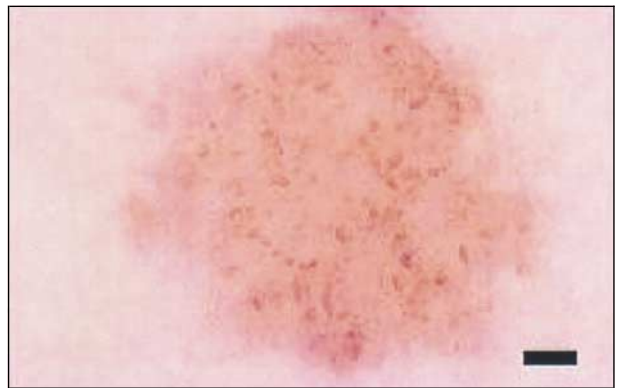


Figure 6. Globular-homogeneous type of Clark nevus. Scale bar indicates 1 mm.

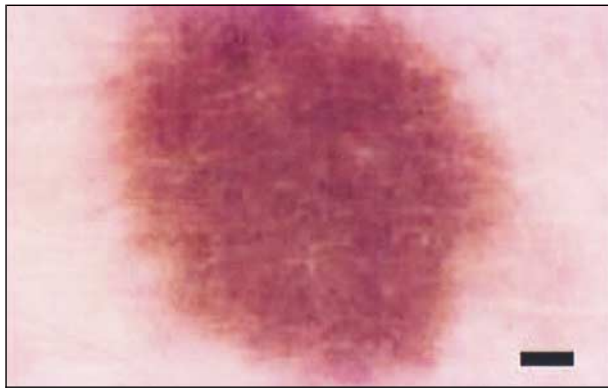


Figure 3. Homogeneous type of Clark nevus. Scale bar indicates 1 mm.

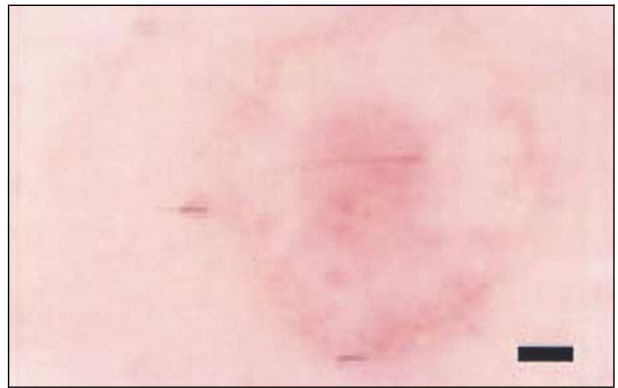

Figure 7. Unclassified type of Clark nevus. Scale bar indicates 1 mm.

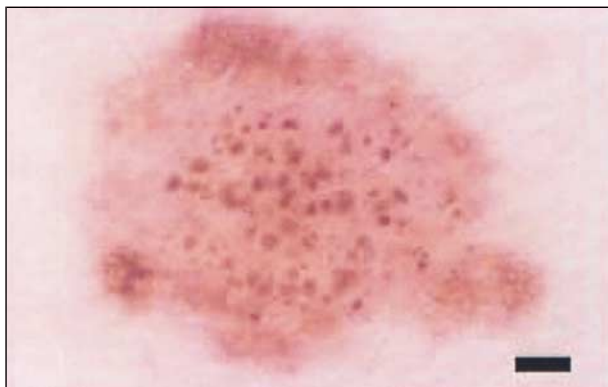


Figure 4. Reticular-globular type of Clark nevus. Scale bar indicates 1 mm.

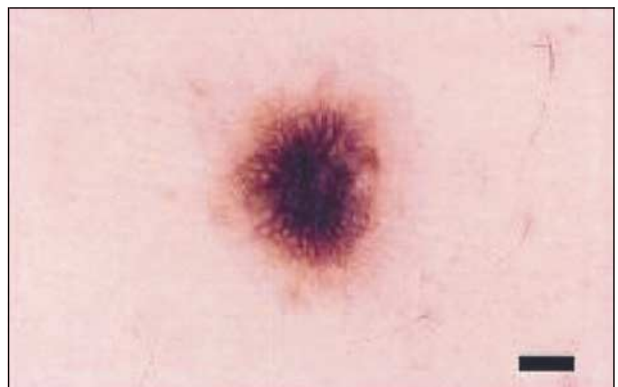


Figure 8. Central hyperpigmented type of Clark nevus. Scale bar indicates 1 mm.

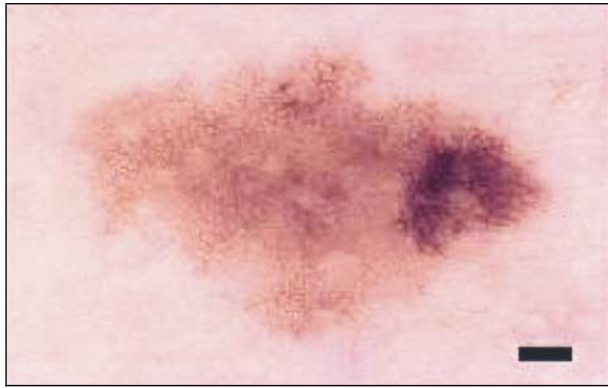

Figure 9. Eccentric peripheral hyperpigmented type of Clark nevus. Scale bar indicates 1 mm.

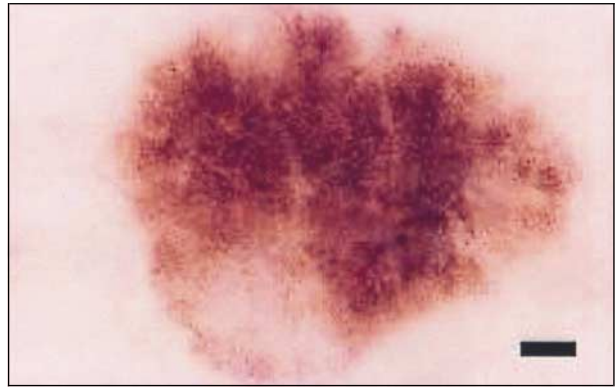


Figure 11. Eccentric hypopigmented type of Clark nevus. Scale bar indicates 1 mm.

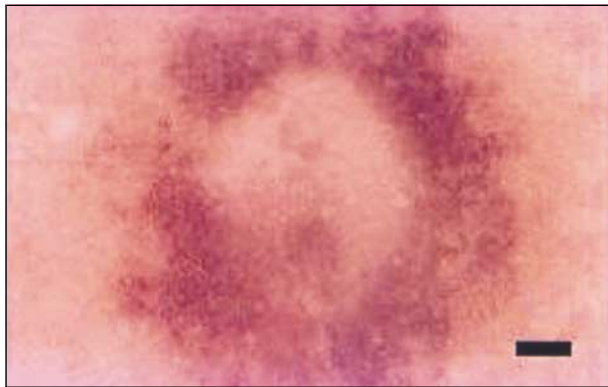

Figure 10. Central hypopigmented type of Clark nevus. Scale bar indicates 1 mm.

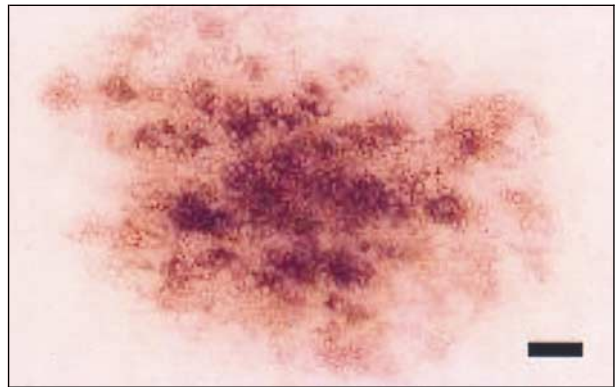


Figure 12. Multifocal hyperpigmented and hypopigmented type of Clark nevus. Scale bar indicates 1 mm.

99.0% of the 829 Clark nevi we examined. The most common type of Clark nevus was the reticular type, followed by the reticular-homogeneous and globular-homogeneous types. In addition, the nevi were classified by pigmentation distribution into the following 3 groups of nearly equal size: 273 Clark nevi had uniform pigmentation, 236 nevi had multifocal hyperpigmentation or hypopigmentation, and the other 312 Clark nevi had central or eccentric hyperpigmentation or hypopigmentation. The most common heterogeneous distribution of pigmentation was multifocal hyperpigmentation or hypopigmentation, followed by central hypopigmentation and central hyperpigmentation. Eccentric peripheral hyperpigmentation was found in only 62 (7.5%) Clark nevi, usually in the reticular or the reticular-homogeneous type of Clark nevus. Eccentric peripheral hyperpigmentation is also often found in malignant melanoma.¹² Thus, Clark nevi with eccentric peripheral hyperpigmentation should be regarded as the most relevant simulators of melanoma within the morphologic spectrum of Clark nevus. Therefore, this type of Clark nevus should be excised or monitored using digital dermoscopy at 3-month intervals. When the eccentric peripheral hyperpigmentation increases, excision of the lesion is necessary.

Few detailed clinical descriptions of special variants of Clark nevi have been given in the literature.^{6,7} Friedman et al⁶ described a dark or light target type of Clark nevus. In our classification, this description refers to Clark nevi with central hyperpigmentation or

hypopigmentation. Most of these variations are seen in the reticular, reticular-homogeneous, and globular-homogeneous types.

The reticular-homogeneous type with central hyperpigmentation in our dermoscopic classification refers to the hypermelanotic nevus described recently by Cohen et al¹⁵ and to the *new nevus of midlife* described by Clark et al.¹⁶ Another characteristic dermoscopic pattern of Clark nevi is a patchy distribution of pigmentation, simulating, at least to a certain degree, the uneven pigmentation observed commonly in melanoma.¹⁰⁻¹³ This patchy distribution is a variation of the reticular pattern in which the presence of several small, isolated areas without pigment network leads to multifocal hypopigmentation. Another variation of the reticular type is characterized by multifocal zones of prominent, dark-brown to black pigmented network structures in a patchy distribution. Clark nevi with the reticular pattern and uneven pigmentation are especially prone to overdiagnosis as melanoma.

Remarkably, most individuals had 1 predominant type of Clark nevus. These specific features of all nevi in a given patient have to be taken into account to determine whether a pigmented lesion should be excised. A lesion that does not belong to the predominant type of Clark nevus in a given patient should be considered an atypical lesion and therefore deserving of special attention. The predominance of a single clinical type of nevus has been also documented by Grob and Bonerandi.¹⁷

Table 2. Classification of Clark Nevi (Atypical Melanocytic Nevi) According to Pigmentation

Pigmentation	Definition	Figure*
Central hyperpigmentation	Hyperpigmented area (significantly darker than the entire lesion) surrounded by fainter parts of the lesion	8
Eccentric peripheral hyperpigmentation	Hyperpigmented area (significantly darker than the entire lesion) reaching 1 part of the border of the lesion	9
Central hypopigmentation	Hypopigmented area (significantly fainter than the entire lesion) surrounded by darker parts of the lesion	10
Eccentric peripheral hypopigmentation	Hypopigmented area (significantly fainter than the entire lesion) reaching 1 part of the border of the lesion	11
Multifocal hyperpigmentation and hypopigmentation	Patchy distribution of hyperpigmented and hypopigmented areas	12

*Each type of nevus is depicted in the following figures.

Table 3. Major Dermoscopic Types of Clark Nevi (Atypical Melanocytic Nevi) and Their Distribution of Pigmentation*

Type (No. [%] of Nevi)	Uniform Pigmentation	Central Hyperpigmentation	Eccentric Peripheral Hyperpigmentation	Central Hypopigmentation	Eccentric Peripheral Hypopigmentation	Multifocal Hyperpigmentation and Hypopigmentation
Reticular (n = 221 [26.9])	76	34	34	26	2	49
Reticular-globular (n = 112 [13.6])	23	19	2	15	5	48
Reticular-homogeneous (n = 167 [20.3])	42	25	12	32	5	51
Globular (n = 84 [10.2])	41	3	3	6	0	31
Globular-homogeneous (n = 148 [18.0])	53	18	7	21	6	43
Homogeneous (n = 89 [10.8])	38	9	4	13	11	14
Total (n = 821)†	273 (33.3)	108 (13.2)	62 (7.6)	113 (13.8)	29 (3.5)	236 (28.7)

*Data are given as number of Clark nevi classified; totals are given as number (percentage). Percentages have been rounded and may not sum 100.

†Sample for analysis was restricted to the 821 Clark nevi that could be classified from the total sample size of 829 Clark nevi.

Every new classification should fulfill at least the following 3 criteria: it should be easily applicable, it should be reproducible, and it should open new aspects. With the caveats that dermoscopic-histopathologic correlation has not yet been attempted and that the reproducibility of the classification has not yet been demonstrated, our proposed dermoscopic classification of Clark nevi fulfills all these criteria. The classification is easily applicable because only 3 main dermoscopic patterns and 2 descriptors of pigmentation have to be analyzed. The concentration on reticular, globular, and homogeneous patterns and on hypopigmentation and hyperpigmentation also minimizes the subjective variation in the assessment of dermoscopic features. Stanganelli et al¹⁸ found perfect intraobserver agreement for pigment network in 100% of 150 digital dermoscopic images, for diffuse (eg, homogeneous) pigmentation in 97%, and for globules in 85%. The descriptors of chromatic characteristics are usually less reproducible, but intraobserver agreement was seen for hypopigmentation (also called depigmentation) in 91% of digital dermoscopic images.¹⁸ The main difficulty in our classification system was whether a nevus with unevenly distributed pigmentation should be classified as hypopigmented or hyperpigmented. However, by using the color of the main part of the nevus as a reference, this judgment also can be reproducible.

Finally, better characterization of Clark nevi offers the opportunity to study their biological features. An exact and practicable classification of Clark nevi is a prerequisite for further studies concerning the morpho-

logic changes of these acquired melanocytic nevi by means of digital dermoscopic follow-up examinations.¹⁹⁻²¹ Furthermore, it may be important to investigate whether a particular dermoscopic type of Clark nevi is more often associated with development of cutaneous melanoma. Obviously, a meticulous dermoscopic-histopathologic correlation as outlined recently²² for each different dermoscopic type of Clark nevus would be suitable.

Our dermoscopic classification of Clark nevi (atypical melanocytic nevi) should be regarded not just as an academic morphologic exercise but as a classification system that will also lead to a better understanding of the biological characteristics of these common melanocytic lesions.

Accepted for publication May 23, 2001.

This study was supported by a grant from Österreichische Krebshilfe Steiermark, Graz, Austria.

We thank Barbara J. Rutledge, PhD, for editing assistance.

Corresponding author and reprints: H. Peter Soyer, MD, Department of Dermatology, University of Graz, Auenbruggerplatz 8, A-8036, Graz, Austria (e-mail: peter.soyer@uni-graz.at).

REFERENCES

- Clark WHJ, Reimer RR, Greene M, Ainsworth AM, Mastrangelo MJ. Origin of familial malignant melanomas from heritable melanocytic lesions: "the B-K mole syndrome." *Arch Dermatol.* 1978;114:732-738.
- Elder DE, Goldman LI, Goldman SC, Greene MH, Clark WHJ. Dysplastic nevus

- syndrome: a phenotypic association of sporadic cutaneous melanoma. *Cancer*. 1980;46:1787-1794.
3. Barnhill RL, Roush GC, Duray PH. Correlation of histologic architectural and cytoplasmic features with nuclear atypia in atypical (dysplastic) nevocytic nevi. *Hum Pathol*. 1990;21:51-58.
 4. Seywright MM, Doherty VR, MacKie RM. Proposed alternative terminology and subclassification of so-called "dysplastic naevi." *J Clin Pathol*. 1986;39:189-194.
 5. Ackerman AB, Magana-Garcia M. Naming acquired melanocytic nevi: Unna s, Miescher s, Spitz s, Clark s. *Am J Dermatopathol*. 1990;12:193-209.
 6. Friedman RJ, Heilman ED, Rigel DS, Kopf AW. The dysplastic nevus: clinical and pathologic features. *Dermatol Clin*. 1985;3:239-249.
 7. McBride A, Rivers JK, Kopf AW, et al. Clinical features of dyplastic nevi. *Dermatol Clin*. 1991;9:717-722.
 8. Ackerman AB, Massi D, Nielson TA. *Dysplastic Nevus: Atypical Mole or Typical Myth?* Philadelphia, Pa: Ardor Scribendi Ltd; 1999.
 9. Garbe C, Büttner P, Weiss J, et al. Associated factors in the prevalence of more than 50 common melanocytic nevi, atypical melanocytic nevi, and actinic lentiginos: multicenter case-control study of the central malignant melanoma registry of the German Dermatological Society. *J Invest Dermatol*. 1994;102:700-705.
 10. Bahner FA, Fritsch P, Kreusch J, et al. Terminology in surface microscopy. *J Am Acad Dermatol*. 1990;23:1159-1162.
 11. Soyer HP, Smolle J, Hödl S, Pachernegg H, Kerl H. Surface microscopy: a new approach to the diagnosis of cutaneous pigmented tumors. *Am J Dermatopathol*. 1989;11:1-10.
 12. Kenet RO, Kang S, Kenet BJ, Fitzpatrick TB, Sober AJ, Barnhill RL. Clinical diagnosis of pigmented lesions using digital epiluminescence microscopy: grading protocol and atlas. *Arch Dermatol*. 1993;129:157-174.
 13. Pehamberger H, Binder M, Steiner A, Wolff K. In vivo epiluminescence microscopy: improvement of early diagnosis of melanoma. *J Invest Dermatol*. 1993;100(suppl):356S-362S.
 14. Steiner A, Binder M, Schemper M, Wolff K, Pehamberger H. Statistical evaluation of epiluminescence microscopy criteria for melanocytic pigmented skin lesions. *J Am Acad Dermatol*. 1993;29:581-588.
 15. Cohen LM, Bennon SD, Johnson TW, Golitz LE. Hypermelanotic nevus: clinical, histopathologic, and ultrastructural features in 316 cases. *Am J Dermatopathol*. 1997;19:23-30.
 16. Clark WH Jr, Elder DE, Guerry D, Epstein MN, Green MH, Van Horn M. A study of tumor progression: the precursor lesions of superficial spreading and nodular melanoma. *Hum Pathol*. 1984;15:1147-1165.
 17. Grob JJ, Bonerandi JJ. The "ugly duckling" sign: identification of the common characteristics of nevi in an individual as a basis for melanoma screening. *Arch Dermatol*. 1998;134:103-104.
 18. Stanganelli I, Burroni M, Rafanelli S, Bucchi L. Intraobserver agreement in interpretation of digital epiluminescence microscopy. *J Am Acad Dermatol*. 1995;33:584-589.
 19. Stolz W, Schiffner R, Pillet L, et al. Improvement of monitoring of melanocytic skin lesions with the use of a computerized acquisition and surveillance unit with a skin surface microscopic television camera. *J Am Acad Dermatol*. 1996;35:202-207.
 20. Braun RP, Lemonnier E, Guilloid J, Skaria A, Salomon D, Saurat JH. Two types of pattern modification detected on the follow-up of benign melanocytic skin lesions by digitized epiluminescence microscopy. *Melanoma Res*. 1998;8:431-437.
 21. Kittler H, Seltenheim M, Dawid M, Pehamberger H, Wolff K, Binder M. Frequency and characteristics of enlarging common melanocytic nevi. *Arch Dermatol*. 2000;136:316-320.
 22. Soyer HP, Kenet RO, Wolf IH, Kenet BJ, Cerroni L. Clinicopathological correlation of pigmented skin lesions using dermoscopy. *Eur J Dermatol*. 2000;10:22-28.

ARCHIVES Features

1. **Free color publication** if color illustrations enhance the didactic value of the article.
2. **Rapid publication.** The time from acceptance to publication in our March 2001 issue was 3.2 months.
3. **Expedited review** on request from authors.
4. **Archives Express.** Manuscripts with high priority can be reviewed, accepted, and published within 6 to 8 weeks.
5. **Research Trainee Award of \$1000** for the resident or fellow who is the first author of the best research paper of the past year.
6. **Dermatologic Surgery Trainee Award of \$1000** for the resident or fellow who is the first author of the best article on surgical dermatology published in the past year.
7. **Free distribution of the journal** to all residents and clinical dermatologists in the United States.